

Selective Arterial Embolization With Ethylene-Vinyl Alcohol Copolymer for Control of Massive Lower Gastrointestinal Bleeding: Feasibility and Initial Experience

By Jose Urbano, MD, PhD; et al

PURPOSE

To evaluate the safety, efficacy, and clinical outcomes of superselective embolization using ethylene-vinyl alcohol copolymer (Onyx™ liquid embolic system) as the primary treatment for acute and massive lower gastrointestinal bleeding (LGIB).

MATERIALS AND METHODS

Between January 2008 and October 2013, all patients with focal massive LGIB who were treated by embolization were retrospectively analyzed. Onyx™ liquid embolic system was chosen as the embolic agent in all cases in an intention-to-treat fashion. Embolization was indicated in 31 consecutive patients (mean age, 80 y \pm 11.1). Multidetector computed tomography and digital subtraction angiography were performed in all patients.

CLINICAL OUTCOME

By intention-to-treat, the clinical success of embolization with the Onyx™ liquid embolic system for LGIB was 96.7%. Immediate and long-term control of bleeding was obtained in 100% of the patients who could undergo embolization, stabilizing the level of hemoglobin in the blood and alleviating rectal bleeding or melena. None of the patients who underwent embolization required any other invasive treatment for bleeding control during the follow-up period. The 30-day re-bleeding rate was 10% (three cases); the bleeding was minimal and self-limited in all cases.

LONG-TERM OUTCOMES

The mean follow-up time was 23.7 months (range, 1-71 months). Two patients died during follow-up at 4 months after the embolization; both of these patients did not have additional episodes of LGIB. The remaining patients were alive at the conclusion of the study. One patient with rectal neoplasia received neoadjuvant chemotherapy and radiation therapy, and an oncologic surgical resection was performed 3 months after the embolization. None of the patients exhibited clinical intestinal subocclusion or obstruction during the follow-up period.

DISCUSSION

In the present study, embolization of massive LGIB using Onyx™ liquid embolic system 18 LES could be applied in 30 of 31 patients. The technical success rate was 93.5% (29 of 31 cases). Immediate and long-term

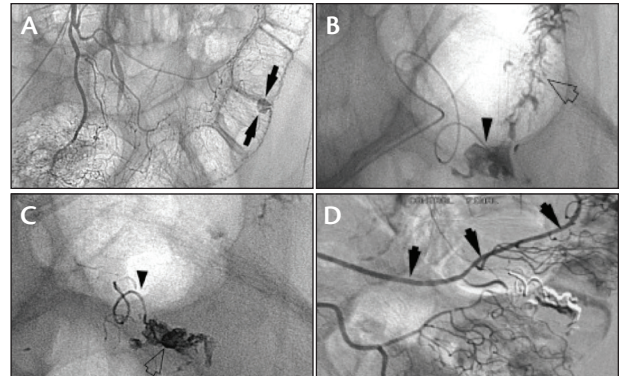


Figure 1. Angiography of the inferior mesenteric artery reveals active bleeding from a diverticulum in the left colon (arrows) (A). Microcatheter tips at the bleeding site (arrowhead) and contrast extravasation toward the colonic lumen (arrow) (B). Mold of Onyx™ liquid embolic system filling the vasa recta responsible for the bleeding (arrow) and Onyx extravasation through the bleeding site toward the intestinal lumen (arrowhead) (C). Final control angiography shows untouched marginal artery (arrows) (D).

control of LGIB was obtained in 100% of the patients who could undergo embolization, with no major complications or procedure-related deaths.

Although microcoils are the most frequent embolic agent utilized for embolization of LGIB, Onyx™ liquid embolic system is a very good alternative. Onyx™ liquid embolic system produces a plug in the eroded artery and simultaneously blocks the primary site of the bleeding. The slow real-time injection under fluoroscopic guidance provides greater control over the distribution of the embolization agent, avoiding nontargeted embolization. Because this product is nonadhesive, the microcatheter is not entrapped. Coagulopathy is a negative predictive factor for survival, bleeding control, and rebleeding in patients with LGIB. Onyx™ liquid embolic system has the remarkable advantage of acting independently of any underlying coagulopathy or low platelet count.

Compared to cyanoacrylates, the main concern is the uncontrolled release, which is associated with a high risk of distal migration and nontargeted embolization, as well as the risk of causing severe intestinal ischemia. Risk related to microcatheter entrapment is also a major concern. ■

Reprinted from JVIR, Vol. 25, No. 6, Urbano J, Cabrera M, Franco A, Alonso-Burgos A. Selective arterial embolization with ethylene-vinyl alcohol copolymer for control of massive lower gastrointestinal bleeding: feasibility and initial experience, Pages No. 839-846, Copyright 2014, with permission from Elsevier.